Virchows Arch (2000) 437:133–137 © Springer-Verlag 2000

ORIGINAL ARTICLE

**Sumika Okamoto · Masanori Hisaoka**
**Masahiro Ushijima · Shosaku Nakahara**
**Satoshi Toyoshima · Hiroshi Hashimoto**

# Activating *Gsα* mutation in intramuscular myxomas with and without fibrous dysplasia of bone

Received: 10 December 1999 / Accepted: 22 February 2000

**Abstract** Activating missense mutations in the Arg 201 codon of the gene encoding the α subunit of Gs, the G protein that stimulates cAMP formation, have been recognized as the cause of many endocrine diseases, McCune-Albright syndrome and isolated fibrous dysplasia of bone. On the other hand, intramuscular myxomas with fibrous dysplasia, so-called Mazabraud's syndrome, have been sporadically reported, but it has not been confirmed whether intramuscular myxoma, with or without fibrous dysplasia, is associated with the *Gsα* mutations. We investigated the presence of the *Gsα* mutations in intramuscular myxomas with or without fibrous dysplasia by a PCR-SSCP assay, using formalin-fixed, paraffin-embedded tissues. In five of the six intramuscular myxomas (three with and two without fibrous dysplasia), point mutations were detected as aberrant bands by SSCP, which were confirmed by a subsequent sequence analysis (three Arg to His and two Arg to Cys). This result suggests that the *Gsα* mutations are related to tumorigenesis in intramuscular myxoma and that intramuscular myxoma is one of the diseases induced by abnormal Gsα protein.

**Key words** *Gsα* · Intramuscular myxoma · Fibrous dysplasia · Mazabraud's syndrome · McCune-Albright syndrome

S. Okamoto · M. Hisaoka · H. Hashimoto (✉)
Department of Pathology and Oncology, School of Medicine, University of Occupational and Environmental Health, 1-1 Iseigaoka, Yahatanishi-ku, Kitakyushu 807-8555, Japan
e-mail: hiroshi@med.uoeh-u.ac.jp
Tel.: +81-93-6917239, Fax: +81-93-6920189

M. Ushijima
Department of Orthopedics, Kitakyushu Municipal Medical Center, Kitakyushu, Japan

S. Nakahara
Department of Surgery, Kitakyushu Municipal Medical Center, Kitakyushu, Japan

S. Toyoshima
Department of Pathology, Kitakyushu Municipal Medical Center, Kitakyushu, Japan

## Introduction

G proteins (guanine nucleotide-binding proteins) mediate between a variety of transmembrane receptors and intracellular responses in the signal transduction pathway and regulate cell proliferation, differentiation and apoptosis [6]. A number of human diseases have been described as a consequence of the mutations of the gene encoding the α-subunits of G protein [25, 27]. The activating missense mutations in Arg201 codon of the gene for the α-subunit of the stimulatory G protein (Gsα) have been specifically associated with some kinds of endocrine tumors [32], abnormal endocrine and nonendocrine tissues, such as café-au-lait pigmentation and fibrous dysplasia (FD) of bone, in McCune-Albright syndrome (MAS) [16, 19, 21, 22, 24] and FD of bone without associated MAS [5, 12, 23]. Abnormal G protein derived from the mutant *Gsα* gene has been identified as an inhibitor of an intrinsic GTPase activity that leads to constitutive activation of adenylyl cyclase and increased levels of cyclic AMP, thus resulting in diverse biological consequences [12, 26]. Accordingly, the mutant *Gsα* gene is known as the *gsp* oncogene [6, 12]. Mutant *Gsα* genes encoding codon 201 in substitution for wild-type CGT (Arg) are CAT (His), TGT(Cys) and AGT (Ser) [9].

MAS is a sporadic disease characterized by the triad of polyostotic FD and café-au-lait pigmentation, and hyperfunction of multiple endocrine glands. The clinical signs vary from one case to another, and incomplete forms of MAS may occur [13, 18, 25]. These manifestations may have accounted for a postzygotic somatic cell mutation resulting in a mosaic population of cells with and without the *Gsα* mutation [8]. The mutant gene has been identified in a variable number of cells in different affected tissues of a patient, and has also been expressed in only a small proportion of cells in nonaffected tissues or blood leukocytes [19, 21, 22, 28]. More recently, the same mutation has been detected in monostotic or polyostotic FDs without abnormality of endocrine function or skin pigmentation [5, 23].

Intramuscular myxoma (IM) is a relatively uncommon benign tumor of the soft tissue and accounts for ap-

**Table 1** Summary of clinical details and mutation analyses in samples of intramuscular myxoma and fibrous dysplasia of bone (*IM* intramuscular myxoma, *FD* fibrous dysplasia, MAS McCune-Albright syndrome)

| Sample no. | Age (years)/sex | Site | Special features | Gsα mutation |
|---|---|---|---|---|
| IM in FD+IM | | | | |
| 1 | 42/F | Upper arm, thigh, abdominal wall | =Sample 7 +MAS | Arg→His |
| 2 | 46/F | Bilateral, thighs | +Polyostotic FD | Arg→His |
| 3 | 70/F | Buttock | +Polyostotic FD | Arg→Cys |
| IM without FD | | | | |
| 4 | 68/F | Thigh | | Arg→His |
| 5 | 63/F | Lower leg | | Arg→Cys |
| 6 | 78/F | Buttock | | not done |
| FD in FD+IM | | | | |
| 7 | 42/F | Clavicle (skull, humerus) | =Sample 1 +MAS | Arg→His |
| FD without IM | | | | |
| 8 | 37/F | Femur | | Arg→His |
| 9 | 65/M | Rib | | Arg→His |
| 10 | 30/M | Rib | | Arg→Cys |
| 11 | 35/M | Humerus | | Arg→Cys |
| 12 | 27/F | Femur | | Arg→His |

proximately 0.1% of soft tissue tumors [7, 9]. Mazabraud's syndrome is known as a rare disorder with both multiple IMs and polyostotic FD and occasionally involves some of the context of MAS [1, 3, 15, 30]. To our knowledge, there have been no investigations aimed at determining whether IM arising in Mazabraud's syndrome is related to the same *Gsα* gene mutation.

In this paper we discuss the PCR-SSCP analysis that we conducted to ascertain the presence of the *Gsα* gene mutation in IMs and FDs, including Mazabraud's syndrome and MAS, and the significance of the *Gsα* mutation in IMs with and without FD.

## Materials and methods

### Materials

Twelve samples from 11 patients were retrieved from the Department of Pathology and Oncology, School of Medicine, University of Occupational and Environmental Health. The clinical details recorded for these 12 samples are summarized in Table 1. The lesions were six IMs (3 with FD, 3 without FD) and six FDs (1 with IM, 5 without IM). One of the 11 patients was an example of an MAS sufferer having both multiple IM and polyostotic FD with a history of precocious puberty, and this case has previously been published as a case report (samples 1 and 7) [26]. This patient also had invasive ductal carcinoma of the breast, which led to breast-conserving surgery with lymph node dissection. A sample from the breast cancer, the axillary lymph nodes and the peripheral blood of the patient were also investigated. Clinicopathological features of the 2 cases with Mazabraud's syndrome (sample 2 and 3) have been reported elsewhere [1]. Non-affected tissues of the remaining 5 patients with IM were not available. None of the samples from the 6 FDs was treated with decalcification. Other soft tissue myxoid tumors, including 3 myxoid liposarcomas, 3 myxoid malignant fibrous histiocytomas, 3 extraskeletal myxoid chondrosarcomas, 2 nerve sheath myxomas, 1 low-grade fibromyxoid sarcoma and 1 ossifying fibromyxoid tumor of soft parts, were also investigated in this study as negative controls.

### PCR-SSCP assay

Genomic DNA was extracted from formalin-fixed, paraffin-embedded tissues of the lesions using a DNA extraction kit (Sepagene, Sankojunyaku, Tokyo, Japan) according to the manufacturer's instructions, after deparaffinization and 3 days' digestion with proteinase K (Merck, Darmstadt, Germany). Polymerase chain reaction (PCR) was carried out to amplify the *Gsα* gene with the primers for exon 8, as previously reported by Candeliere et al. [5]. The forward primer was 5'-CCATTGACCTCAATTTTGTT TCAG-3' and the reverse primer, 5'-GGTAACAGTTGGCTTA CTGGAAGTTG-3'. The reaction mixture was composed of 100 ng genomic DNA, 12.5 pmol of each primer, 200 μM dNTP, and 2.5 U of Pfu DNA polymerase (Native Pfu, Stratagene, La Jolla, Calif.) in a standard reaction buffer (10 mM Tris-HCl, 50 mM KCl, 1.5 mM MgCl2 and 0.001% gelatin). PCR consisted of 40 cycles of denaturation for 45 s at 94°C, annealing for 45 s at 60°C and strand elongation for 45 s at 72°C. The amplified exon of the *Gsα* gene was screened by single-strand conformation polymorphism (SSCP) analysis using 3 μl PCR product in sample-denaturing buffer (99% formamide, 5 mM Tris-HCl, 0.5 mM EDTA 0.05% xylene cyanol and 0.05% bromophenol blue). After denaturation at 95°C for 10 min, the samples were loaded onto a precast polyacrylamide ready-to-run gel (GeneGel Excel 12.5/24, Pharmacia Biotech, Uppsala, Sweden) and kept at 15°C for 90 min with a Peltier temperature-regulated electrophoresis unit (GenePhor, Pharmacia Biotech). To visualize nucleic acids in the gel, a silver staining kit (Bio-Rad, Hercules, Calif.) was used. Aberrant bands were excised using a clean scalpel blade, and PCR products extracted from the removed bands were reamplified using Taq DNA polymerase (AmpliTaq Gold, Perkin-Elmer, Norwald, Conn.) under the same conditions as described above for the initial amplification. To confirm the mutation, the PCR products were cloned into a pCR2.1 vector (Invitrogen, San Diego, Calif.) by TA ligation and sequenced using an automated sequencer (ALFexpress, Pharmacia Biotech, Uppsala, Sweden).

## Results

Microscopically, all the six IMs were composed of sparsely distributed bland spindle or stellate cells in an abundant myxoid matrix, but the vasculature was poor (Fig. 1A). The histological features of all bone lesions in this study were characteristic of fibrous dysplasia, consisting of woven bone separated by fibrous tissue (Fig. 1B). Each of the 12 samples yielded one major band of the predicted size for exon 8 of the *Gsα* gene (115 bp).

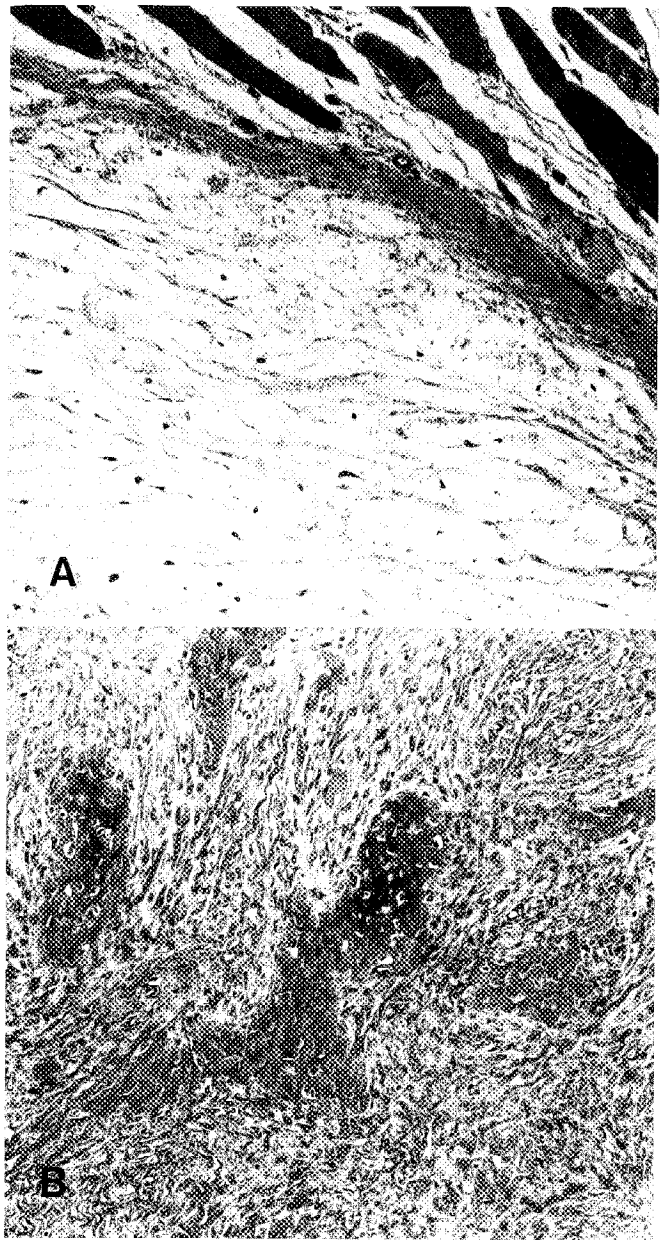


**Fig. 1A, B** Histological features of intramuscular myxoma and fibrous dysplasia of bone in a patient with McCune-Albright syndrome. **A** intramuscular myxoma showing the paucity of both constituent spindle or stellate cells and vasculature, and an abundance of mucoid material. **B** Fibrous dysplasia of the clavicle displaying irregular trabeculae of woven bone separated by fibrous tissue

The SSCP analysis using the PCR products disclosed aberrant bands in 5 of the 6 IMs (3 with FD, 2 without FD) and all of the 6 FDs (1 with IM, 5 without IM; Fig. 2). Subsequent determination of the sequences showed missense mutation at codon 201 in exon 8 of the *Gsα* gene as follows: 3 of 6 IMs and 4 of 6 FDs, G–A transitions (Arg to His); 2 of 6 IMs and 2 of 6 FDs, C–T transitions (Arg to Cys) (Fig. 3). In the case with MAS, the same *Gsα* mutation (Arg to His) was detected in both the IM (sample 1) and the FD (sample 7). There was the same




**Fig. 2** Single-strand conformation polymorphism analysis of exon 8 of the *Gsα* gene. Aberrant bands are seen in 11 of 13 lanes, that is, not in *lanes 6* and *PB*. The *numbers* of the *lanes* are identical to the sample numbers in Table 1 (*PB* normal peripheral blood mononuclear cells, i.e. controls)

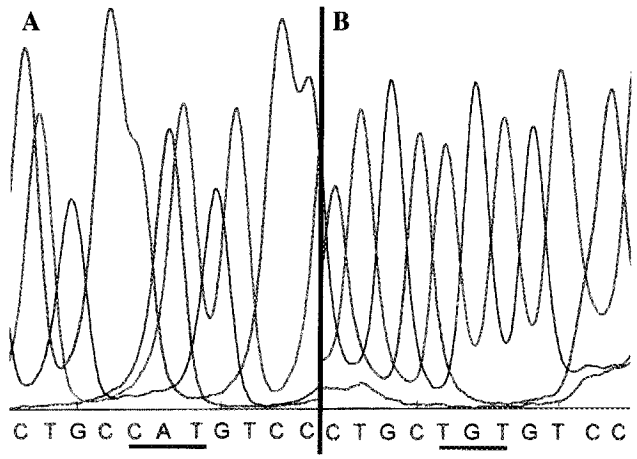


**Fig. 3** Representative examples of sequences of PCR-amplified DNA extracted from aberrant bands by SSCP. G-to-A mutation (**A**) and C-to-T mutation (**B**), encoding Arg201, are *underlined*

*Gsα* mutation in each lesion of the multiple IMs in two cases (samples 1 and 2). The result of each sample is shown in Table 1. By SSCP analysis it was seen that there were no aberrant banding patterns in the breast cancer, lymph nodes and peripheral blood of the patient with MAS and other soft tissue myxoid tumors.

## Discussion

IM is a rare benign soft tissue tumor of unknown origin [7]. Although the association of soft tissue myxoma with osteitis fibrosa was first described by Henschen in 1926 [11], Mazabraud et al., in reporting their second case in 1967, emphasized that the association of IM with FD was occasionally accompanied by some contexts of MAS, and this was not purely a coincidence but a particular form of FD [15]. To our knowledge, only 35 cases of Mazabraud's syndrome have been reported in the literature [3]. The implication of the association of IM with FD has not been made clear. Some authors have speculated the possibility of an underlying localized metabolic error in both tissues [30]. Recent molecular analyses have suggested that mutations of *Gsα* protein are implicated in the development of multiple endocrinopathies of MAS, and possibly in the development of FD of bone [5, 16, 19, 21–23, 28]. Therefore, we hypothesized that the same mutations might be also responsible for the development of IM.

The PCR-SSCP analysis in this study indicates that Arg201 mutations of *Gsα* gene that have been reported in FD are also detected in IM. In the case with MAS, the *Gsα* mutations were detected both in IM and FD, whereas aberrant bands could not be recognized by this technique in the specimens from the breast cancer and from the lymph nodes and peripheral blood of the patient concerned, showing that the mutant gene was present in much higher abundance in IM and FD than in the other tissues examined. Furthermore, the *Gsα* mutations were detected in IM without FD. Therefore, the activating *Gsα* mutations may play an important part in the development of the lesion of IM not only in MAS / Mazabraud's syndrome but also in isolated IM without FD. The results also suggest that IM may be one of the disorders caused by abnormal Gsα protein.

Shenker et al. explained that the *Gsα* mutation might occur early in embryogenesis and give rise to the widespread abnormalities in MAS, whereas the mutation later in life appears to be the basis of restricted tissue disorders, including functioning pituitary adenomas, thyroid adenomas and polyostotic or monostotic FD [23]. That means the diversity in the clinical findings of disorders caused by the *Gsα* mutation lies at the site and time when the mutation occurs during development. Wirth et al. pointed out that IM in a patient with Mazabraud's syndrome was first noticed years or even decades later than FD [30]. We speculate that the mutation may be a later event in IM than in FD. In addition, because IM is almost always multiple in Mazabraud's syndrome, the mutation-bearing cells in an organ of the skeletal muscle are probably distributed in mosaic as well as in café-au-lait pigmentation in the skin, and as polyostotic FD in the bone.

Yamamoto et al. demonstrated that intracellular cAMP content and IL-6 secretion by cultured cells isolated from FDs of MAS patients were increased, and suggested that increased IL-6 induced by the decrease in GTPase activity and the constitutive increase in cAMP content due to the abnormal Gsα protein led to an increased number of osteoclasts, resulting in excessive bone resorption [31]. They speculated that the increased IL-6 had a pathogenic role in FD of MAS patients. Recently, Marie et al. reported that cell proliferation evaluated by DNA synthesis was greater and cell differentiation by the synthesis of osteocalcin, which is a marker for mature osteoblasts, was poorer in the mutation-bearing osteoblastic cells isolated from FD than in normal cells isolated from a nonaffected bony area in the same patient [14]. Riminucci et al. documented that the woven bone of FD in MAS contained an abnormal complement of bone matrix proteins, which enriched anti-adhesion molecules (versican and osteonectin) and reduced pro-adhesive molecules (osteopontin and bone sialoprotein) [16]. Also, Candeliere et al. showed that c-*fos* proto-oncogene containing a functional cAMP response element and its protein are overexpressed in FD [4]. Thus, the data gleaned from these recent observations have clarified the nature of FD. Some investigators described how understanding of the pathogenesis of FD could provide a new strategy for the therapy of FD [25, 31]. Although the mechanism of tumorigenesis is still unclear, it is likely that the *Gsα* mutation in IM provides abnormal cell proliferation and differentiation in primitive mesenchymal cells, including a mucin-secreting activity or expression of another oncogene concerned transcription.

None of the other soft tissue myxoid tumors investigated by the SSCP assay in our study, which included myxoid liposarcoma, myxoid malignant fibrous histiocytoma, extraskeletal myxoid chondrosarcma, low-grade fibromyxoid sarcoma, nerve sheath myxoma and ossifying fibromyxoid tumor of soft parts, exhibited aberrant bands. This result suggests that the *Gsα* mutation is highly specific for IM. Boson et al. demonstrated that no *Gsα* mutation was detected in sporadic odontogenic myxomas and concluded that the mutation was rarely, if ever, associated with such tumorigenesis [2]. Their observations may indicate that the pathogenesis of IM is different from that of odontogenic myxoma.

A variety of techniques for detection of the *Gsα* mutations in tissues of MAS and FD have been designed, such as allele-specific oligonucleotide hybridization [21, 22, 32], direct sequencing of PCR products [29], denaturing gradient gel electrophoresis [2, 16], allele-specific PCR [17] and allele-specific restriction analysis [4, 13] and its modification [5]. In this study, we adopted PCR-SSCP assay for selective amplification of the mutant gene, because the number of mutation-bearing cells was expected to be small. In addition, reamplification using DNA template screened by SSCP achieved sequential enrichment of the mutant gene. The reason why the aberrant band in one of the 6 IMs in the current study could not be detected by the PCR-SSCP may be that SSCP is inherently unable to always detect the mutation from the PCR products, because the sensitivity for detecting the point mutation in PCR products of less than 200 bp by SSCP was reported to be 70–95% [10, 20]. We believe, however, that the PCR-SSCP assay is a convenient and reliable tool for the study of the Arg201 mutations in the *Gsα* gene.

In conclusion, the results of this study emphasize that the Arg201 mutations of the *Gsα* gene exist in IMs whether or not they are associated with FD, and suggest that the mutations may play an important part in tumorigenesis in IM as well as of FD.

**Acknowledgements** The authors are grateful to Dr. Shohei Shimajiri, University of Occupational and Environmental Health, for his critical comments. We also thank Atsuko Tanaka and Megumi Katayama for their technical assistance. This work was supported in part by a 1998 Grants-in-Aid from the Ministry of Education, Science Sport and Culture (08670229) and the Vehicle Racing Commemorative Foundation.

## References

1. Aoki T, Kouho H, Hisaoka M, Hashimoto H, Nakata H, Sakai A (1995) Intramuscular myxoma with fibrous dysplasia: A report of two cases with a review of the literature. Pathol Int 45:165–171

2. Boson WL, Gomez RS, Araujo L, Kalapothakis E, Friedman E, De Marco L (1998) Odontogenic myxomas are not associated with activating mutations of the *Gs alpha* gene. Anticancer Res 18:4415–4417
3. Cabral CEL, Guedes P, Fonseca T, Rezende JF, Cruz LC, Smith J (1998) Polyostotic fibrous dysplasia associated with intramuscular myxomas: Mazabraud's syndrome. Skeletal Radiol 27:278–282
4. Candeliere GA, Glorieux FH, Prud'homme J, St Arnaud R (1995) Increased expression of the c-*fos* proto-oncogene in bone from patients with fibrous dysplasia. N Engl J Med 332:1546–1551
5. Candeliere GA, Roughley PJ, Glorieux FH (1997) Polymerase chain reaction-based technique for the selective enrichment and analysis of mosaic arg201 mutations in Gαs from patients with fibrous dysplasia of bone. Bone 21:201–206
6. Dhanasekaran N, Tsim ST, Dermott JM, Onesime D (1998) Regulation of cell proliferation by G proteins. Oncogene 17:1383–1394
7. Enzinger FM (1965) Intramuscular myxoma. A review and follow up study of 34 cases. Am J Clin Pathol 43:104–113
8. Happle R (1986) The McCune-Albright syndrome: a lethal gene surviving by mosaicism. Clin Genet 29:321–324
9. Hashimoto H, Tsuneyoshi M, Daimaru Y, Enjoji M, Shinohara N (1986) Intramuscular myxoma. A clinicopathologic, immunohistochemical, and electron microscopic study. Cancer 58: 740–747
10. Hayashi K, Yandell DW (1993) How sensitive is PCR-SSCP? Hum Mutat 2:338–346
11. Henschen F (1926) Fall von Ostitis fibrosa mit multiplen Tumoren in der umgebenden Muskulatur. Verh Dtsch Ges Pathol 21:93–97
12. Landis CA, Masters SB, Spada A, Pace AM, Bourne HR, Vallar L (1989) GTPase inhibiting mutations activate the α chain of Gs and stimulate adenylyl cyclase in human pituitary tumours. Nature 340:692–696
13. Malchoff CD, Reardon G, MacGillivray DC (1994) An unusual presentation of McCune-Albright syndrome confirmed by an activating mutation of the Gs alpha-subunit from a bone lesion. J Clin Endocrinol Metab 78:803–806
14. Marie PJ, Pollak C, Chanson P, Lomri A (1997) Increased proliferation of osteoblastic cells expressing the activating Gsα mutation in monostotic and polyostotic fibrous dysplasia. Am J Pathol 150:1059–1069
15. Mazabraud A, Semat P, Roze R (1967) A propos de l'association de fibromyxomes des tissus mous a la dysplasie fibreuse des os. Presse Med 75:2223–2228
16. Riminucci M, Fisher LW, Shender A, Spiegel AM, Bianco P, Robey PG (1997) Fibrous dysplasia of bone in the McCune-Albright syndrome. Am J Pathol 151:1587–1600
17. Riminucci M, Liu B, Corsi A, Shenker A, Spiegel AM, Robey PG, Bianco P (1999) The histopathology of fibrous dysplasia of bone in patients with activating mutations of the *Gsα* gene: site-specific patterns and recurrent histological hallmarks. J Pathol 187:249–258
18. Schwartz RA, Spicer MS, Leevy CB, Ticker JB, Lambert WC (1996) Cutaneous fibrous dysplasia: an incomplete form of the McCune-Albright syndrome. Dermatology 192:258–261
19. Schwindinger WF, Francomano CA, Levine MA (1991) Identification of a mutation in the gene encoding the α subunit of the stimulatory G protein of adenylyl cyclase in McCune-Albright syndrome. Proc Natl Acad Sci USA 89:5152–5156
20. Sheffield VD, Beck JS, Kwitek AE, Sandstrom DW, Stone EM (1993) The sensitivity of single-strand conformation polymorphism analysis for the detection of single base substitutions. Genomics 16:325–332
21. Shenker A, Weinstein LS, Moran A, Pescovitz OH, Charest NJ, Feuillan PP, Spiegel AM (1993) Severe endocrine and nonendocrine manifestations of the McCune-Albright syndrome associated with activating mutations of stimulatory G protein Gs. J Pediatr 123:509–518
22. Shenker A, Weinstein LS, Sweet DE, Spiegel AM (1994) An activating Gsα mutation is present in fibrous dysplasia of bone in the McCune-Albright syndrome. J Clin Endocrinol Metab 79:750–755
23. Shenker A, Chanson P, Weinstein LS, Chi P, Spiegel AM, Lomri A, Marie PJ (1995) Osteoblastic cells derived from isolated lesions of fibrous dysplasia contain activating somatic mutations of the *Gsα* gene. Hum Mol Genet 4:1675–1676
24. Singer FR (1997) Commentary: fibrous dysplasia of bone. The bone lesion unmasked. Am J Pathol 151:1511–1515
25. Spiegel AM (1997) The molecular basis of disorders caused by defects in G proteins. Horm Res 47:89–96
26. Tanabe Y, Nakahara S, Mitsuyama S, Ono M, Toyoshima S (1998) Breast cancer in a patient with McCune-Albright syndrome. Breast Cancer 5:175–178
27. Weinstein LS, Shenker A (1993) G protein mutations in human disease. Clin Biochem 26:333–338
28. Weinstein LS, Shenker A, Gejman PV, Merino MJ, Friedman E, Spiegel AM (1991) Activating mutations of the stimulatory G protein in the McCune-Albright syndrome. N Engl J Med 325:1688–1695
29. Williamson EA, Johnson SJ, Foster S, Kendall-Taylor P, Harris PE (1995) G protein gene mutations in patients with multiple endocrinopathies. J Clin Endocrinol Metab 80: 1702–1705
30. Wirth WA, Leavitt D, Enzinger FM (1971) Multiple intramuscular myxomas. Another extraskeletal manifestation of fibrous dysplasia. Cancer 27:1167–1173
31. Yamamoto T, Ozono K, Kasayama S, Yoh K, Hiroshima K, Takagi M, Matsumoto S, Michigami T, Yamaoka K, Kishimoto T, Okada S (1996) Increased IL-6 production by cells isolated from the fibrous bone dysplasia tissues in patients with McCune-Albright syndrome. J Clin Invest 98:30–35
32. Yoshimoto K, Iwahana H, Fukuda A, Sano T, Itakura M (1993) Rare mutations of the *Gs* alpha subunit gene in human endocrine tumors. Cancer 72:1386–1393