NIH RELAIS Document Delivery

NIH-10082496

NIH -- W1 JO602U

JANICE LEE
NIDCR/NIH, bldg 30, rm 229
Bethesda, MD 20892

ATTN:		SUBMITTED:	2001-12-03 17:17:21
PHONE:	301-435-1674	PRINTED:	2001-12-05 11:47:43
FAX:	-	REQUEST NO.:	NIH-10082496
E-MAIL:		SENT VIA:	LOAN DOC
			5181625

NIH Fiche to Paper Journal

TITLE:	JOURNAL OF CRANIOFACIAL SURGERY
PUBLISHER/PLACE:	Little, Brown And Company Boston Ma
VOLUME/ISSUE/PAGES:	1998 Jan;9(1):79-82 79-82
DATE:	1998
AUTHOR OF ARTICLE:	Gurler T; Alper M; Gencosmanoglu R; Totan S; Guner U; Ak
TITLE OF ARTICLE:	McCune-Albright syndrome progressing with severe f
ISSN:	1049-2275
OTHER NOS/LETTERS:	Library does NOT report holding title 9010410 9558573
SOURCE:	PubMed
CALL NUMBER:	W1 JO602U
NOTES:	i do not have an ip address at this terminal.
REQUESTER INFO:	JANICELEE
DELIVERY:	E-mail: jlee@dir.nidcr.nih.gov
REPLY:	Mail:

NOTICE: THIS MATERIAL MAY BE PROTECTED BY COPYRIGHT LAW (TITLE 17, U.S. CODE)

McCune-Albright Syndrome Progressing With Severe Fibrous Dysplasia

Tahir Gürler, MD
Mehmet Alper, MD
Reha Gençosmanoğlu, MD
Serhat Totan, MD
Ulvi Güner, MD
Yalçin Akin, MD

İzmir, Turkey

We present the case of an 11-year-old girl with McCune-Albright syndrome associated with severe fibrous dysplasia. In addition to bone lesions, she has apparent manifestations of precocious puberty. In examination, a mass at the mentum spreading to mandibular corpus bilaterally was seen. This mass has affected the mandibular teeth. It was nearly 20 × 20 × 15 cm in size and had local necrotic regions on it. The lower lip was expanded too much by the mass. Another mass filled the left maxillary sinus, expanding the left zygomatic region outwardly and closing the left nasal fossa completely. A rectangular skull shape was related to the involvement of cranial bones. After stainless steel, custom-made mandibular prosthesis was prepared, the patient

cocious puberty.[1,2] The syndrome has also been called osteitis fibrosa cystica, osteodystrophia fibrosa, and osteofibroma, until it was named McCune-Albright syndrome. More than 100 cases have been reported, and the male–female ratio is 3:2.[3]

In general, skin lesions are evident in early infancy and are of the café au lait type. As the patient ages, these pigmentations may become darker brown. A direct proportion between the size of the pigmentations and the severity of bone involvement and endocrinological dysfunctions has been reported.[4,5] Endocrine disorders are mainly represented as sexual precocity, which is particularly evident in girls. Laboratory findings are usually within normal limits except for an occasional rise in alkaline phosphatase and estrogen levels.[6]

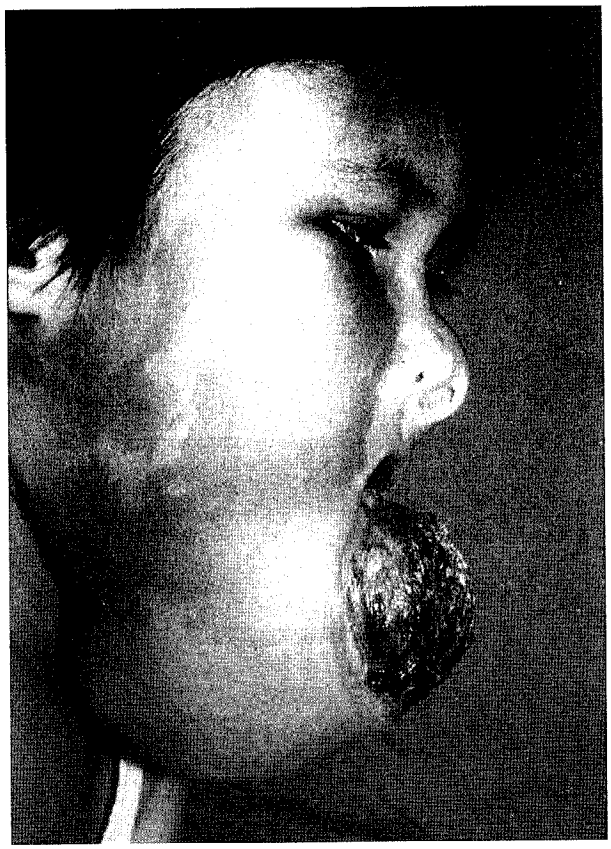

Fig 3 Lateral aspect of mandibular mass.

found (Fig 4). The patient underwent surgery after the completion of routine analysis. The expanded lower lip was opened at the midline. We reached to the tumoral mass and mandible with mucosal incisions through the lower vestibular fold. Although the entire mandible was attacked by fibrous dysplasia, a partial mandibulectomy and tumoral mass excision were performed. Afterward, mandibular parts were carved in both sides and the tips of a custom-made prothesis were placed and was fixed with bone cement.

The lower lip was joined at the midline, and its expanded parts were removed at the upper area. A Weber-Ferguson-Longwire incision was made on the left side, and the mass, which covered the left maxillary sinus was excised with chisels. The operation was completed by suturing all the incisions. No surgical complication developed postoperatively (Fig 5).

Even though pre- and postoperative routine analyses were in normal range, the postoperative blood glucose level was 294 mg%. Required insulin management and diet were implemented. On postoperative day 3, blood glucose level was normal.

Discussion

Pediatricians and endocrinologists are concerned about McCune-Albright syndrome. Because nothing about its cause and pathogenesis is certain, patient follow-up and treatment are crucial. Of the three components of this syndrome—multifocal fibrous dysplasia in bones, widespread café au lait spots, and precocious puberty—the latter is the most important.

Pathologic fractures, especially in the femur, caused our patient to crawl on all fours. Because craniofacial involvement occurs in 100% of disseminated cases, plastic surgeons are often consulted. In such involvements, multiple pathological cranial base fractures, deafness, optic atrophy, and neuralgia caused by pressure to cranial nerves were reported.[12] Although it is rarely reported in dental literature,[6] in 20% of our cases, mandibular involvement was found. However, in studied literature, these mandibular lesions were not found to be as dramatic or severe as in our patient. In fibrous dysplasia associated with McCune-Albright's syndrome, a malignant degeneration such as osteogenic sarcoma was re-

Fig 4 Tomographic view of the lesion.

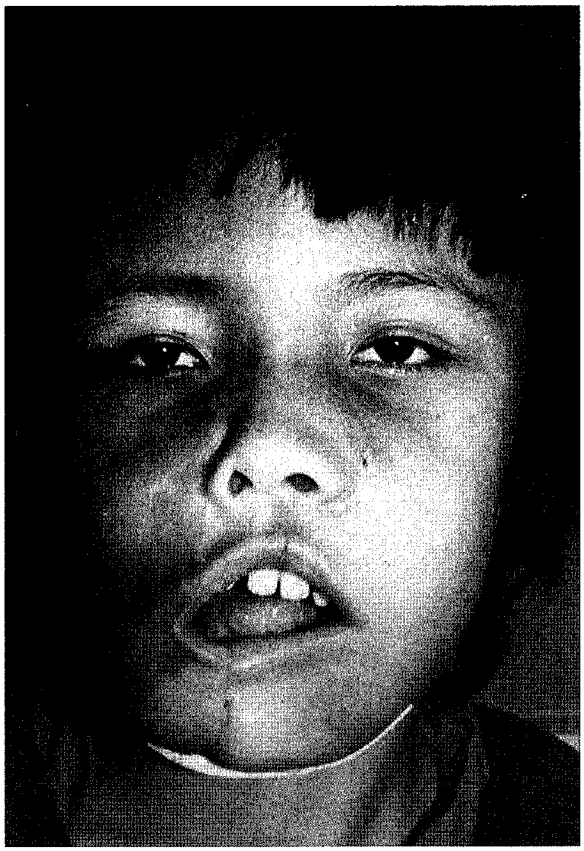

Fig 5 Postoperative appearance of the patient.

ported.[13] There was no malignancy in this case. Endocrinological disorders, such as Cushing's disease, goiter, hyperparathyroidism, acromegaly, hypothalamic diabetes mellitus, hyperthyroidism, and hyperprolactinemia may be associated with this syndrome.[6,7,12]

Hyperparathyroidism, histiocytosis, multiple myeloma, Paget's disease, juvenile Paget's disease, neurofibromatosis, and cherubism should be included in the differential diagnosis of bone lesions of McCune-Albright's syndrome.[14]

Some endocrinologic disorders such as thyroid storm have been reported in surgical patients with McCune-Albright syndrome[15]; however, no problem has occurred in our patient other than hyperglycemia, which continued in first 2 postoperative days.

Our patient is still under observation by the Department of Pediatric Endocrinology to detect new genetic findings in light of the latest literature and to manage the therapeutic procedures.

References

1. McCune DJ. Osteitis fibrosa cystica: the case of a nine year old who also exhibits precocious puberty, multiple pigmentation of the skin and hyperthyroidism. Am J Dis Child 1936;52:743–747
2. Albright F, Butler AM, Hampton AO, Smith P. Syndrome characterized by osteitis fibrosa disseminata, areas of pigmentation and endocrine dysfunction, with precocious puberty in females. N Engl J Med 1937;216:726–746
3. Jones KL. Smith's recognizable patterns of humans malformations, ed 4. Philadelphia: WB Saunders, 1988:454–455
4. DiGeorge AM. Albright syndrome: is it coming of age? J Pediatr 1975;87:917, 1018–1020
5. Gorlin RJ, Pindborg JJ, Cohen MM. Syndromes of the head and neck, ed 2. New York: McGraw-Hill, 1976:441–445
6. Triantafillidou K, Antoniades K, Karakasis D, et al. McCune-Albright Syndrome: report of a Case. Oral Surg Oral Med Oral Pathol 1993;75:571–574
7. Comite F, Shawker TH, Pescovitz OH, et al. Cyclical ovarian function resistant to treatment with an analogue of luteinizing hormone releasing hormone in McCune Albright syndrome. N Engl J Med 1984;311(16):1032–1036
8. Nager GT, Kennedy DW, Kopstein E. Fibrous dysplasia: a review of the disease and its manifestations in the temporal bone. Ann Otol Rhinol Laryngol 1982;91(Suppl);92:5–52
9. Zachariades N, Papanicolau S, Xypolyta, et al. Albright syndrome. Int J Oral Surg 1984;13:53–58
10. Pfeffer S, Molina E, Feunillan P, et al. McCune Albright syndrome: the patterns of scintigraphic abnormalities. J Nucl Med 1990;31:1474–1478
11. Kreutziger KL. Giant fibrous dysplasia of the mandible, surgical management. Laryngoscope 1989;99:618–630
12. Maccari S, Fornaciari G, Bassi C, et al. Contraceptive methods in the McCune-Albright syndrome. Clin Exp Obstet 1989;16:129–130
13. Hall MB, Sclar AG, Gardner DF. Albright's syndrome with reactivation of fibrous dysplasia secondary to pituitary adenoma and further complicated by osteogenic sarcoma. Oral Surg 1984;57:616–619
14. Edgerton MT, Persing JA, Jane JA. The surgical treatment of fibrous dysplasia. Ann Surg 1985;202:459–479
15. Lawless ST, Reeves G, Bowen R. The development of thyroid storm in a child with McCune-Albright syndrome after orthopedic surgery. Am J Dis Child 1992;146:1099–1102